



INTRODUCTION

Hyaluronic acid (HA) is a glycosaminoglycan that is part of the extracellular matrix. It is secreted by multiple cells such as fibroblasts, synoviocytes, endothelial cells, smooth muscle cells, adventitious cells and oocytes. It forms part of tissue and cellular matrices, and stabilizes the cellular components of the dermis, regulating osmotic balance, cell proliferation, adhesion and migration. Since the first case of pneumonia reported in Wuhan in December 2019 by the new coronavirus SARS-CoV-2, the pandemic has originated more than 207,780,000 infected worldwide. In addition to the effect of the virus on key organs, leading to respiratory diseases, anosmia, diarrhea, fever and other complications, late inflammatory reactions to dermal fillers of hyaluronic acid, especially in the face, were also reported after confirmed SARS-CoV and infections and in vaccinated individuals. These changes appear both in patients positive for the virus, regardless of systemic symptomatology, and in patients who received vaccination against SARS-CoV. Although reactions are self-limited and self-soluble, it is important to know how to diagnose them and to establish treatments with corticoids, hyaluronidase and/or antibiotics. However, given that materials are increasingly durable and that the disease is still ongoing, there are new vaccines in development, it is essential to conduct studies that describe the long-term evolution of both HA reactions and other bioimplants.

METHODS & MATERIAL

A literature review of the current literature was performed. The following words were searched in PubMed search engines: Hyaluronidase, COVID 19; SARS-CoV; Hyaluronic acid; Late immune reaction ; Inflammation enzyme ACE.. The search was conducted from 2021 to 2023.

RESULTS

Especially for patients with discussed risk factors, procedures can be planned with a time window to minimize the risk of reactions. Although the data may be evolving rapidly, given what is known so far, providers may consider a 4-8 week window between filling injections and vaccination for the general population and potentially longer for those with autoimmune risk factors or immune disorders, chemotherapeutic or immunomodulatory drugs and those with a history of sensitivity to dermal fillers (i.e., pronounced and late swelling compared to expected for a given filler).

DISCUSSION

Munavalli et al.(2021) were the first to describe these changes in several patients, how they performed the diagnosis, treatment and results obtained. They report the use of lisinopril (angiotensin conversion enzyme inhibitor) as an innovative treatment in these reactions. They presented 4 cases of late inflammatory reaction (DIR) to dermal facial filling with hyaluronic acid quickly after vaccination for COVID-19. All dirs (Late Immediate Reactions) occurred after a hyaluronic acid filler was placed more than 1 year before vaccination. Among the existing theories about or why two DTRs (Delayed Hypersensitivity Reações) are seen with dermal pre-enchimento after certain immunogenic triggers (COVID-19 or other vaccines). Some theories relate that the pre-enzymes may act as an adjuvant before instead of direct activators of T cells, increasing the antigen-specific immune response, without triggering one on its own. Likewise, in genetically predisposed individuals, there is a lower limit so that vaccinations, infections or other inciting factors trigger inflammatory reactions (Alijotas-Reig et al., 2018). Certain predisposing factors can cause susceptibility to HA pre-enlightenment DTRs, including injuries, dental procedures, medications, and procedures (facial erythema and edema after influenza-like illness; (Belezny et al., 2015, Turkmani et al., 2019). documented in other cases swelling and nodules in the early stages of acute sinusitis, 2 to 4 months after the last injection of pre-enrichment with HA (Humphrey et al., 2020). In cases of facial edema, studies will show resolution with short courses of oral steroids (<2 weeks), which does not seem to alter the efficacy of the vaccines and, if necessary, hyaluronidase for residual or prolonged edema (Belezny et al., 2015, Pathmanathan and Dzienis, 2019, Turkmani et al., 2019).

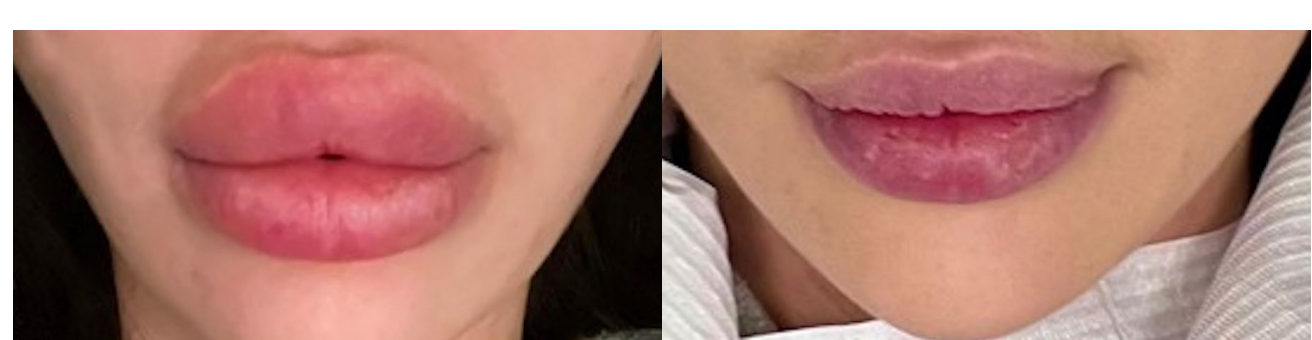


Figure 1: A - 36-48 hours after booster with Pfizer vaccine. Note the enlarged and edematous upper and lower lips, which can be confused with angioedema. B - Lips two weeks after conservative treatment (Obagi S, Obagi Z, Altawaty Y, Obagi Z)

Table 1. Frequency of solicited local cutaneous adverse reactions within 7 days after each vaccination: a comparison of vaccines that reached phase 3 trials.

Requested adverse reaction	Vaccine Pfizer dose 1	Placebo dose 1	Vaccine Pfizer dose 2	Placebo dose 2	Vaccine Moderna dose 1	Placebo dose 1	Vaccine Moderna dose 2	Placebo dose 2	AstraZeneca dose 1	AstraZeneca dose 2
redness	104/2238 (4.5)	26/2248 (1.1)	123/2045 (5.9)	14/2053 (0,7)	345/11401 (3.0)	46/11404 (0,4)	928/10357 (9.0)	42/10317 (0,4)	1/128 (0,7)	2/128 (1,5)
swelling	132/2238 (5.8)	11/2248 (0,5)	132/2045 (6.3)	5/2053 (0,2)	768/11401 (6,7)	33/11404 (0,3)	1309/10357 (12.6)	35/10317 (0,3)	2/128 (1,5)	2/128 (1,5)

Sources: Ramasamy et al., 2021 ; US Food Administration information documents for Pfizer-BioNTech and Modern COVID-19 vaccines.

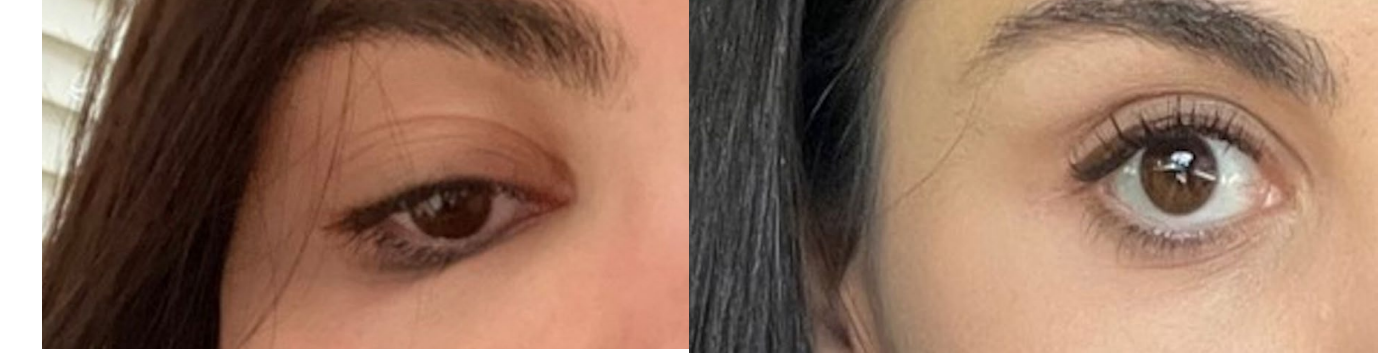

Figure 2: A - 36-48 hours after Pfizer vaccine booster. note the inflamed and swollen skin overlying the infraorbital and tear duct. B - The eye of the same patient two weeks after under eye filler hyaluronidase dissolution. (Obagi S, Obagi Z, Altawaty Y, Obagi Z)

CONCLUSION

With the development of new drugs and vaccines, much of our knowledge about side effects, especially rare ones, is discovered after these drugs reach the market and are implemented in the population at magnitudes much higher than the clinical trial. Late immunological reactions secondary to vaccination are self-limited and minor, so the possibility of complications arising from facial filling should in no case discourage vaccination. It is recommended to wait at least three weeks after vaccination with COVID-19 to perform the refills and thus avoid the peak of the immune response produced at 21 days. The importance of adequate patient selection and subsequent follow-up is emphasized, and that aesthetic procedures are performed by physicians with adequate training, capable of diagnosing and treating possible complications.

REFERENCES

- V. López Pérez. COVID-19 and Dermal Fillers: Should We Really Be Concerned? *Actas Dermosifiliogr.* 2022 Oct;113(9):888-894. English, Spanish. doi: 10.1016/j.ad.2022.05.019. Epub 2022 Jun 2. PMID: 35659611; PMCID: PMC9159960.
- V. López Pérez, COVID y rellenos faciales ,realmente debemos preocuparnos? ,*Actas Dermo-Sifiliográficas*, Volume 113, Issue 9,2022,Pages 888-894,ISSN 00017310,https://doi.org/10.1016/j.ad.2022.05.019.(https://www.sciencedirect.com/science/article/pii/S0001731022004689).
- Shauna M Rice, Sarah D Ferree, Natasha Atanaskova Mesinkovska, Arianne Shadi Kourosh, The art of prevention: COVID-19 vaccine preparedness for the dermatologist, *International Journal of Women's Dermatology*, Volume 7, Issue 2, 2021, Pages 209-212, ISSN 2352-6475, https://doi.org/10.1016/j.ijwd.2021.01.007. (https://www.sciencedirect.com/science/article/pii/S2352647521000083)
- J. Alijotas-Reig et al.,2013 , MT Fernández-Figueras , L. Puig Reações adversas inflamatórias de início tardio relacionadas a injeções de preenchimento de tecidos moles *Clin Rev Allergy Immunol* , 45 (1) (2013) , pp . 97 – 108.
- K. Belezny et al,2015 , JDA Carruthers , A. Carruthers , ME Mummert , S. Humphrey, Nódulos de início tardio secundários a um preenchimento coesivo de ácido hialurônico de 20 mg/mL: causa e tratamento,*Dermatol Surg* , 41 (8) (2015) , pp . 929 – 939.
- MG Turkmani et al, 2019 , K. De Boule , WG Philipp-Dormston,Reação de hipersensibilidade retardada ao preenchimento dérmico de ácido hialurônico após doença semelhante à gripe ,*Clin Cosmet Investig Dermatol* , 12 (2019) , p. 277.
- S. Humphrey , DH Jones , JD Carruthers , A. Carruthers , K. Belezny , N. Wesley , et al, 2020,Revisão retrospectiva de eventos adversos tardios secundários ao tratamento com preenchimento suave e coeso de ácido hialurônico de 20 mg/mL em 4.500 pacientes,*J Am Acad Dermatol* , 83 (1) (2020) , pp . 86-95.
- S. Pathmanathan , M. Dzienis, 2019, Reação de preenchimento dérmico associada a cetuximabe, *BMJ Case Rep* , 12 (8) (2019) , Artigo e228882.
- Obagi S, Obagi Z, Altawaty Y, Obagi Z. Tratamento da resposta inflamatória tardia ao preenchimento de tecidos moles com ácido hialurônico em indivíduo imunizado Moderna após reforço com vacina Pfizer com hialuronidase. *Surg Cosmet Dermatol.* 2022;14:e20220149.